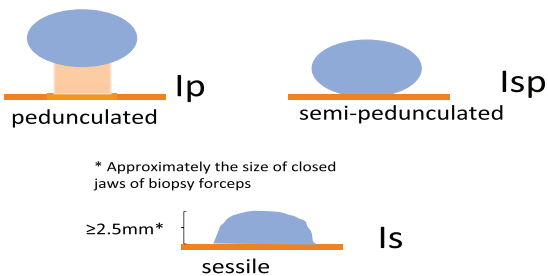


Paris Classification

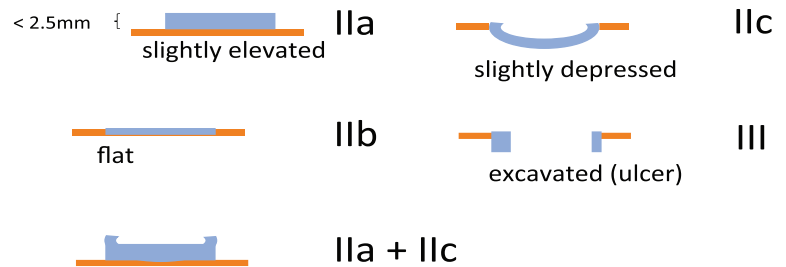
The Paris endoscopic classification of superficial neoplastic lesions

All mucosal polyps are considered superficial according to the Paris classification and are therefore labelled type "0" below

Protruding



Non-protruding (Flat)



NICE Classification

Narrow-band imaging international colorectal endoscopic (NICE) classification

	Colour	Vessels	Surface Pattern	Most likely pathology	Examples
Type 1	Same or lighter than background	None, or isolated lacy vessels coursing across the lesion	Dark or white spots of uniform size, or homogenous absence of pattern	Hyperplastic	
Type 2	Browner relative to background (verify colour arises from vessels)	Brown vessels surrounding white structures**	Oval, tubular or branched white structure surrounded by brown vessels**	Adenoma***	
Type 3	Brown to dark brown relative to background; sometimes patchy whiter areas	Has area(s) of disrupted or missing vessels	Amorphous or absent surface pattern	Deep submucosal invasive cancer	

* Can be applied using colonoscopes with or without optical (zoom) magnification.

** These structures (regular or irregular) may represent the pits and the epithelium of the crypt opening.

*** Type 2 consists of Vienna classification types 3, 4 and superficial 5 (all adenomas with either low or high grade dysplasia, or with superficial submucosal carcinoma). The presence of high grade dysplasia or superficial submucosal carcinoma may be suggested by an irregular vessel or surface pattern, and is often associated with atypical morphology (e.g. depressed area).