



User's Guide for the Synoptic MRI Report for Pre-Operative Staging of Rectal Cancer

2015

INSTRUCTIONS

- **This User's Guide accompanies the synoptic MRI report and provides a rationale and detailed explanation of how to report each item on the synoptic MRI report.**
- **Key points are summarized in text boxes at the start of each section. It is recommended that these text boxes are read prior to using the synoptic MRI report.**
- **After each text box a detailed explanation is provided and can be used for your reference as necessary.**

The manual has been updated and reviewed by Dr. Blair MacDonald in 2015.

Written by:

Eisar Al-Sukhni, MD
General Surgery Resident
University of Toronto

Laurent Milot, MD, MSc
Department of Diagnostic Imaging
Sunnybrook Health Sciences Centre
laurent.milot@sunnybrook.ca

Mark Fruitman, MD
Department of Diagnostic Imaging
St. Joseph's Health Centre
mark.fruitman@gmail.com

Gina Brown, MD
Royal Marsden Hospital
Department of Radiology
gina.brown@rmh.nhs.uk

Selina Schmocker, BA(Hons)
Zane Cohen Centre for Digestive Diseases
Mount Sinai Hospital
sschmocker@mtsinai.on.ca

Erin Kennedy, MD, PhD
Division of General Surgery
Mount Sinai Hospital
ekennedy@mtsinai.on.ca

Reviewed by:

Blair MacDonald, MD
Department of Diagnostic Imaging
The Ottawa Hospital
blmacdonald@ottawahospital.on.ca

Kartik Jhaveri, MD
Department of Diagnostic Imaging
University Health Network
kartik.jhaveri@uhn.ca

Dan Gill, MD
Department of Diagnostic Imaging
Windsor Regional Hospital
danny_gill@wrh.on.ca

This project was supported by the Cancer Services Innovation Partnership – a joint initiative of Cancer Care Ontario and the Canadian Cancer Society

Table of Contents

A. CURRENT TREATMENT GUIDELINES FOR RECTAL CANCER.....	3
B. OVERVIEW OF METHODS USED TO DEVELOP THE SYNOPTIC MRI REPORT	4
C. SYNOPTIC MRI REPORT	5
CLINICAL INFORMATION	5
IMAGING PROCEDURE DESCRIPTION.....	5
FINDINGS.....	6
1. TUMOUR LOCATION AND CHARACTERISTICS	6
2. EXTRAMURAL DEPTH OF INVASION AND MR T-CATEGORY.....	6
3. RELATIONSHIP OF THE TUMOUR TO THE MESORECTAL FASCIA (MRF).....	9
4. EXTRAMURAL VASCULAR INVASION	13
5. MESORECTAL LYMPH NODES AND TUMOUR DEPOSITS	15
6. EXTRAMESORECTAL LYMPH NODES.....	17
7. OTHER FINDINGS (COMPLICATIONS, METASTASES, LIMITATIONS OR UNCERTAINTY)	18
IMPRESSIONS	18
D. REFERENCES	19
APPENDIX A: MRI RECTAL STAGING TEMPLATE (2015)	22
CLINICAL INFORMATION	22
IMAGING PROCEDURE DESCRIPTION.....	22
APPENDIX B: TNM Staging Classification	23

A. CURRENT TREATMENT GUIDELINES FOR RECTAL CANCER

- **Current CCO guidelines recommend preoperative chemoradiation for Stage II (T3-T4N0) and Stage III (T1-4N1-2) primary rectal cancer.**
- **PreRT and preCRT significantly reduce the risk of local recurrence but have little effect on overall survival**

Current Cancer Care Ontario (CCO) guidelines recommend preoperative chemoradiation for Stage II (T3-T4N0) and Stage III (T1-4N1-2) primary rectal cancer.¹ These recommendations are based on large randomized controlled trials (RCTs) published in the surgical literature (Table 1) that show that preoperative radiotherapy (preRT) and chemoradiotherapy (preCRT) for Stage II and III rectal cancer significantly reduce the risk of local recurrence but have little effect on overall survival.²⁻⁵

Although an earlier Swedish RCT did show a significant improvement in survival with preRT, the local recurrence rate was 27% in the surgery alone arm, suggesting that total mesorectal excision (TME) or high quality surgery was not performed in all patients.⁶ Due to this finding, it is thought that the preRT compensated for the sub-optimal surgery and led to a survival benefit that has not been reproduced in the other RCTs published subsequently.

Table 1

Trial	N	Description	Local Recurrence (%)		Overall Survival (%)	
			Pre-op RT	No RT	Pre-op RT	No RT
Dutch (NEJM, 2001)	1861	Clinical Stage I-III Pre-op RT vs No Pre-op RT 2 yr follow up	2*	8*	82	82
MRC CR07 NCIC-CTG C016 (Lancet, 2009)	1350	Clinical Stage 1-III Pre-op RT vs selective Post op CRT 5 yr follow up	Pre-op RT	Selective Post- op CRT	Pre-op RT	Selective Post- op CRT
			5.0*	12.0*	70	68
German (NEJM, 2004)	823	Stage II and III Pre-op CRT vs Post-op CRT 5 yr follow up	Pre-op CRT	Post-op CRT	Pre-op CRT	Post-op CRT
			6*	13*	76	74
Polish (BJS, 2006)	312	Stage II and III Pre-op RT vs Pre-op CRT 4 yr follow up	Pre-op RT	Pre-op CRT	Pre-op RT	Pre-op CRT
			9	14	67	66
Swedish (NEJM, 1997)	1168	Stage I-III Pre-op RT vs No Pre-op RT 5 yr follow up	11*	27*	58*	48*

Pre-op RT = preoperative radiation = 25 Gy = 5 fractions X 5 Gy

Pre-op CRT = preoperative chemoradiation = 50.4 Gy = 28 fractions X 1.8 Gy + continuous 5-FU infusion

* denotes p<0.05

B. OVERVIEW OF METHODS USED TO DEVELOP THE SYNOPTIC MRI REPORT

The 2015 release of the Synoptic MRI Template maintains most of the original structure and content of the original template, published in 2012.⁷ An iterative review of the 2012 template was conducted by CCO's Cancer Imaging Program regional imaging leads and their local health integration (LHIN) stakeholders (including colorectal surgeons, MRI radiologists, radiation and medical oncologists, and gastrointestinal multidisciplinary cancer conference (GI MCC) boards) around the province. Each imaging lead approached their collaborating GI MCC team and regional radiologists through emails, and discussion at GI MCC. The changes were proposed and discussed by email involving imaging leads from all the provincial LHINs. Adaptations were consensus-based after carefully considering the many suggestions from frontline users and innovators. When available new evidence was used, but many of the adaptations are of a practical nature reflecting the need for semantic clarification, optimizing readout order, decreasing confusing or overlapping terminology and when possible reducing inter-reader variability. Revisions of the 2012 template were only made when there was high relevance to clinical decision making and strong consensus. Controversial or lower relevance adaptations were rejected and the original template was maintained to the maximum extent possible. The original authors were consulted on all changes and agreed to the improved clarity and value of the approved revisions. The methodology for the 2012 template is described below.

2012 Template

A systematic review of the published literature on the diagnostic accuracy of MRI for staging rectal cancer was performed using Medline, EMBASE and Cochrane databases. The inclusion criteria for the review were: (i) original papers with primary data collection, (ii) use of the pathologic specimen as the gold standard, (iii) published between January 2000 and May 2010, and (iv) English language. The literature search yielded 1145 articles and 109 of those articles met the inclusion criteria and were reviewed in full by 2 GI radiologists and 2 colorectal surgeons. The main findings of the literature review were: (i) involvement of the CRM appeared to be most accurately reported (ii) distinguishing between T2 and T3 tumours is very difficult and (iii) lymph node size was not an accurate predictor of lymph node involvement.

A meta-analysis was then performed using 21 of the studies reviewed to determine the sensitivity, specificity and diagnostic odds ratio for involvement of the CRM, T-category (T1/T2 vs T3/T4), and lymph node status⁸ (Table 2). MRI specificity was significantly higher for CRM involvement (94%, 95% CI 88-97) than for T-category (75%, 95% CI 68-80) and lymph node metastases (71%, 95% CI 59-81). There was no significant difference in sensitivity between the three elements due to wide overlapping confidence intervals. DOR was significantly higher for CRM (56.1, 95% CI 15.3-205.8) than for lymph node metastases (8.3, 95% CI 4.6-14.7) but did not differ significantly from T-category DOR (20.4, 95% CI 11.1-37.3).

Table 2: Sensitivity, specificity, and DOR of MRI for T-category, lymph node metastases and CRM involvement

Parameter	Sensitivity (%)	Specificity (%)	DOR
CRM involvement	77 (95%CI 57-90)	94 (95%CI 88-97)	56.1 (95%CI 15.3-205.8)
T-category	87 (95%CI 81-92)	75 (95%CI 68-80)	20.4 (95%CI 11.1-37.3)
Lymph node metastases	77 (95%CI 69-84)	71 (95%CI 59-81)	8.3 (95%CI 4.6-14.7)

CI, confidence interval; CRM, circumferential resection margin; DOR, diagnostic odds ratio

Based on the results of the literature review, meta-analysis and expert opinion, a synoptic MRI report for primary rectal cancer was developed (Appendix A). The following sections provide a rationale for the items included on this synoptic report. In addition, the TNM classification has been included as a reference in Appendix B.

C. SYNOPTIC MRI REPORT

CLINICAL INFORMATION

Standard formatting was added to the template and includes a section for clinical information. This is an important part of the document and is recommended for all synoptic reporting. The clinical information provided on the requisition should be included as a minimum in this free text section. Individual centers may require specific details from their referring doctors.

IMAGING PROCEDURE DESCRIPTION

The title was changed to reflect standard terminology adopted for all synoptic radiology reporting. In this section the radiologist is asked to comment on the adequacy of the study, the magnet strength, and a free text statement describing the protocol or referring to a standard protocol that can be made available on request. It is acceptable to simply state “The institutional standard rectal cancer staging protocol was used on a 1.5 T or 3 T magnet.” If IV gadolinium or rectal distention is used, then this should also be included in the description. Radiologists/Imaging centers may choose to include sequences description, variations according to local practice or expectations.

- **High resolution, T2-weighted sequences perpendicular to the long axis of the rectum using phased array coil are required in order to acquire appropriate images for rectal cancer.**

To achieve optimal visualization of the rectum and surrounding structures for staging of rectal tumours, the protocol utilized by the MERCURY study group⁹ is recommended (Table 3).

Hardware

Different field strengths may be used with equally good results but require adjustment of imaging parameters to obtain an adequate signal-to-noise ratio. Although endoluminal coil MRI may provide superior imaging resolution¹⁰, due to its limited usefulness in structuring rectal tumours and increased cost, it is less widely used across Ontario. On this basis, the evidence and recommendations outlined in this document are intended specifically to guide the use of pelvic phased array coil MRI.

Patient Preparation

There is some evidence that rectal distension may improve the accuracy of T-category assessment while having little effect on CRM or lymph node assessment.¹¹ Other forms of bowel preparation, enemas, anti-peristaltic agents, and intravenous contrast have not been shown to improve staging accuracy significantly and are not endorsed by the MERCURY study group.¹² For the purpose of the synoptic MRI report, these maneuvers are considered optional and are left to the discretion of the individual radiologist and/or centre.

Sequences

Four fast-spin echo, T2-weighted sequences without fat saturation are recommended, as summarized below (Table 3). Sequences 1 and 2 give a crude visualization of the primary tumour, possible sites of nodal involvement, and orientation of the tumour. They are used to plan sequences 3 and 4, which are the high-resolution sequences. These sequences enable characterization of nodes and detailed staging of the extent of the primary tumour. T1-weighted sequences are not mandatory as they prolong the study and do not provide additional information.

Table 3

Sequence	Imaging plane	TR/TE	FOV (cm)	Section thickness (mm)	Matrix size	ETL	NSA	Comment
1	Sagittal	2500-5000/85	24	5-0	512x256	8	2	Allow visualization of the tumour
2	Axial	4000/85	24	5-0	512x256	8	2	Pelvic sidewall to sidewall, from iliac crest to symphysis pubis
3	Oblique axial	4000/85	16 (20 for 1.0T machines)	3-0	256x256	8	4	Through tumour and perirectal tissues, perpendicular to long axis of rectum
4	Coronal oblique	4000/85	16 (20 for 1.0T machines)	3-0	256x256	8	4	For low rectal tumours (at or below origin of levators)

(Source: MERCURY Study Group. Extramural depth of tumor invasion at thin-section MR in patients with rectal cancer: results of the MERCURY study. *Radiology* 2007;243:132-9.)

FINDINGS

1. TUMOUR LOCATION AND CHARACTERISTICS

A statement about “Tumor at or below the puborectalis” is now moved to this section because it is assessed along with the height of the tumor and anal sphincter involvement.

2. EXTRAMURAL DEPTH OF INVASION AND MR T-CATEGORY

(i) Extramural depth of invasion

- **Extramural depth of invasion (EMD) should be reported for all upper, mid and low T3 and T4 tumours.**
- **EMD is measured for the definitive tumour border only and does not include spiculations into the perirectal fat.**
- **For T1 and T2 tumours, EMD should be recorded as “0mm”.**

Extramural depth of invasion (EMD) is defined as the extension of tumour into the perirectal fat beyond the muscularis propria, and applies to all T3 and T4 tumours. Several retrospective studies have shown that T3 tumours with EMD < 5 mm have improved rates of local recurrence and survival compared to T3 tumours with EMD > 5 mm.^{13, 14} Based on this rationale, the MERCURY trial showed that EMD on MRI is extremely accurate with a mean difference of only -0.05 mm (95% CI: -0.49-0.40 mm) between EMD reported on MRI and the pathologic specimen.⁹

Therefore, EMD is included on the synoptic MRI report. This measurement should be reported for all upper, mid and low T3 and T4 tumours. As per the MERCURY study group, EMD is measured for the definitive tumour border only and does not include spiculations or haziness in the perirectal fat. For T1 and T2 tumours, the EMD should be reported as “0”.

(ii) T-category

- **A range for T-category should be reported (i.e., T2/early T3) if a definitive T-category cannot be accurately assessed**

The review of the literature found that, in studies including T1 to T4 tumours, overstaging, and understaging resulted most often between T2 and T3 tumours (i.e., the threshold for treatment decision-making for preRT and preCRT).¹⁵⁻²¹

In cases where a specific T-category cannot be assigned with certainty, we recommend reporting a range of possible T-categories. Although this is not expected to change the actual accuracy of T-category reporting (which is a limitation of MRI technology), it is anticipated that reporting a range of categories will emphasize that diagnostic uncertainty exists and thereby improve communication between the radiologist and clinical team and assist with treatment decision-making.

Spiculation of the perirectal fat

- **Spiculation of the perirectal fat should be reported as a “T2/early T3 tumour”.**

There is controversy as to whether the pattern of spiculation of the tumour into the perirectal fat should be considered as benign desmoplastic reaction or malignant extension. The MERCURY group, led by Dr Gina Brown, considers this pattern of spiculation into the perirectal fat to represent a T2 tumour (22), whereas another leading group from the Netherlands, led by Dr Regina Beets-Tan, considers this pattern to represent a T3 tumour.¹⁵

To improve consistency in reporting on the synoptic MRI report (not accuracy), it is recommended that the pattern of spiculation of the perirectal fat be reported as “T2/early T3”.

Local invasion beyond the rectum

- **Definite invasion: loss of intervening fat plane and corresponding T2 signal abnormality within the organ.**
- **Possible invasion: loss of intervening fat plane and no corresponding T2 signal abnormality within the organ.**
- **No invasion: preservation of the intervening fat plane.**

The structures listed on the synoptic report are structures that, if involved, would change approach to management.

- Anterior peritoneal reflection (T4a tumor)
- Puborectalis • Levator ani • Obturator • Piriformis • Pelvic bones(specify) • Sacrum (Specify Level)
- Bladder • Ureter(s) • Prostate • Uterus • Vagina • Urethra
- Vascular Involvement of Iliac Vessels • Other

(iii) Low rectal cancer

Clinically, low rectal cancer is defined as rectal cancer located 0 to 5 cm from the anal verge. Generally, the literature shows that the risk of perforation and local recurrence is increased for low rectal cancers.

For the purpose of the synoptic MRI report, low rectal cancers have been classified on MRI into two categories relative to the top border of puborectalis as suggested by the MERCURY group. These categories are: (i) tumours in which the lower extent of the tumour is clearly above the top border of puborectalis and (ii) tumours in which the lower extent of the tumour is at or below the top border of puborectalis^{2,4} (See Figure 1).

Low rectal tumours in which the lower extent of the tumour is above the top border of puborectalis may be amenable to sphincter sparing surgery and are to be reported similarly to upper and mid rectal tumours on the synoptic MRI report.

- **Low rectal tumours in which the lower extent of the tumour is above the top border of puborectalis should be reported similarly to upper and mid rectal tumours on the synoptic MRI report.**

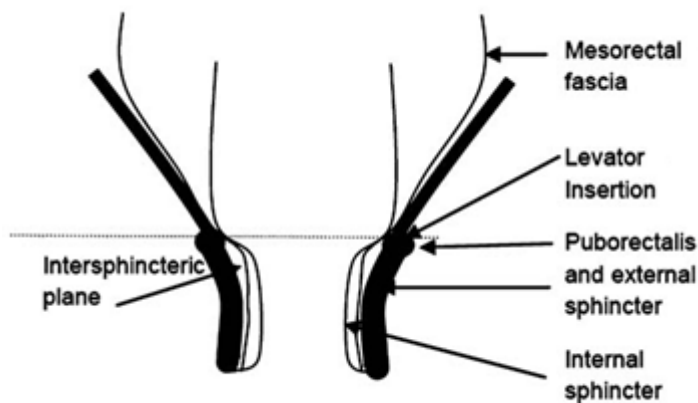


Figure 1:

With permission from Shihab OC, Moran BJ, Heald RJ, Quirke P, Brown G. MRI staging of low rectal cancer. *Eur Radiol.* Mar 2009;19(3):643-650

Low rectal cancers in which the lower extent of the tumour is at or below the top border of puborectalis generally will require an abdominal perineal resection (T1 and early T2), extralevator APR (advanced T2 and T3) or pelvic exenteration (T4).²³

- **For low rectal cancers in which the lower extent is at or below the top border of puborectalis, the depth of invasion for this portion of the tumour should be reported according to the levels shown on the synoptic MRI report.**

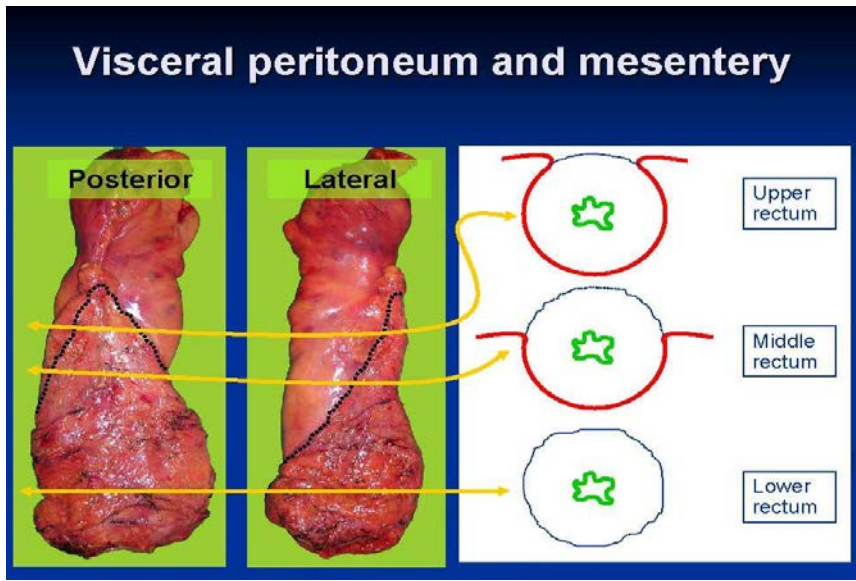
For these tumours, the depth of invasion for the portion of the tumour at, straddling, or below the top border of the puborectalis should be reported according to the following levels on the synoptic MRI report. Note that in the 2015 template, reference to a low rectal T category has been removed and replaced with **Levels** to avoid confusion and contradiction with T-category assignment in the previous section. In addition the description of the **Levels** has been shortened to reduce overlap, and avoid redundant description of T4 disease already addressed in section 3ii) of this report. The new **Levels** are as follows:

- Not applicable (tumor above the puborectalis sling)
- Level 1 (submucosa only, no involvement of internal sphincter)
- Level 2 (confined to the internal sphincter; no involvement of intersphincteric fat)
- Level 3 (intersphincteric fat involved)
- Level 4 (involves external sphincter or beyond)

3. RELATIONSHIP OF THE TUMOUR TO THE MESORECTAL FASCIA (MRF)

- **The CRM is a pathologic term that refers to the surgically dissected surface of the specimen and corresponds to the non-peritonealized aspect of the rectum.**

The CRM is a pathologic term that refers to the surgically dissected surface of the specimen and corresponds only to the non-peritonealized aspect of the rectum. The anterior peritoneal reflection is the transition between the peritonealized and non peritonealized portion of the rectum (Figure 2).



BLUE Line = CRM (non-peritonealized rectum)

RED Line = Peritonealized Rectum (not CRM)

Figure 2:
With permission from Dr. Mahmoud Khalifa, Joint Chief, Anatomic Pathology, Sunnybrook Health Sciences Centre and University Health Network

Based on this pathologic definition, the CRM is only circumferential for rectal tumours below the anterior peritoneal reflection. For upper rectal tumours the CRM is located posteriorly and for upper-mid rectal tumours the CRM is posterior-lateral. Therefore, the CRM does not apply to upper, anterior and anterolateral tumours above the peritoneal reflection where the rectum is peritonealized.

Since the CRM is determined by the extent of the surgical resection, which cannot be predicted on MRI, the term mesorectal fascia or MRF is more appropriate for MRI based staging. Therefore, for the purpose of the synoptic MRI report, the term MRF will be used. Similar to the pathological CRM, the MRF is only circumferential for rectal tumours below the anterior peritoneal reflection and does not apply to upper, anterior and anterolateral tumours above the peritoneal reflection where the rectum is peritonealized.

- **The MRF is only circumferential for rectal tumours below the anterior peritoneal reflection.**
- **The MRF does not apply to anterior, peritonealized surface of the anterior rectum above the anterior peritoneal reflection.**

While Beets-Tan has reported that a minimum distance of 5 mm to the MRF results in a 2 mm CRM, more recently Brown has prospectively demonstrated that a minimum CRM of 1 mm on MRI results in a negative CRM in patients who have had surgery alone or pre-op chemoradiation followed by surgery.^{15,24,25}

This is clinically relevant since a negative CRM (defined as ≥ 1 mm) is associated with a significantly lower risk of local recurrence than a positive CRM (defined as < 1 mm).²⁶

For the synoptic report, the minimum distance to the MRF refers to the shortest distance of the most penetrating component of the definitive tumour border to the MRF, where the definitive tumour border is the nodular or pushing border of the tumour and does not include spiculations or perirectal haziness in the fat.

The minimum distance to the MRF should be reported for all T2 or higher stage tumours where the MRF can be adequately seen or reasonably estimated (i.e. at the level of the prostate and seminal vesicles).

The distance to the MRF should be reported as “not applicable” for any tumour above the peritoneal reflection that involves the peritonealized portion of the rectum (i.e., upper, anterior and anterolateral tumours). This includes T4 tumours involving the peritonealized portion of the rectum (i.e., T4a tumours). For T4 tumour involving adjacent structures (i.e., T4b), the distance to the MRF should be reported as “0”.

- **The minimum distance to the MRF should be reported for all T2 or higher stage tumours where the MRF can be adequately seen or can be reasonably estimated.**
- **The minimum distance to the MRF refers to the shortest distance of the definitive tumour border to the MRF, where the definitive tumour border is the nodular or pushing border of the tumour and does not include spiculations or haziness of the perirectal fat.**
- **If it is not possible to reasonably estimate the MRF, the minimum distance to the MRF should be reported as “unable to assess”.**
- **The distance to the MRF should be reported as “not applicable” for tumours above the peritoneal reflection involving the peritonealized portion of the rectum (including T4a tumours).**
- **For T4 tumours invading adjacent structures, the distance to the MRF should be reported as “0”.**

Special Cases

(i) Spiculation into the perirectal fat

For the purpose of the synoptic report, when spiculation into the perirectal fat is present, the minimum distance from the MRF for the definitive tumour border and the spiculations are to be reported separately. This represents a compromise between the MERCURY approach in which distance to the MRF would be reported from the definitive tumour border not the spiculations (considered T2), and the approach reported by Beets-Tan in which the distance to the MRF is reported from the most penetrating spiculation rather than the definitive tumour border.

- **The minimum distance to the MRF for the definitive tumour border and the spiculations are to be reported separately.**

(ii) Other part of tumour closer to the MRF than most penetrating part of the tumour

In select cases, a different component of the tumour (other than the most penetrating component of the tumour) may be closer to the MRF. This is mostly likely to occur with anterior tumours, that straddle the peritoneal reflection, that have a T3 component above the peritoneal reflection and a T2 component is below the peritoneal reflection. In this circumstance, the minimum distance to the MRF from the most penetrating part of the tumour or T3 component is above the peritoneal reflection and would be reported as “not applicable”. However, the T2 component below the peritoneal reflection may only be 2 or 3 mm from the MRF and may be particularly close to the prostate or vagina. This information is clinically relevant as pre-operative chemoradiation may be considered for a threatened MRF even though the tumour is only T2.

- **If a component of the tumour other than the most penetrating component is closer to the MRF, the minimum distance to the MRF for this other component of the tumour should be reported.**

(iii) Interpretation of the Anterior Peritoneal Reflection

Interpretation of the anterior peritoneal reflection is challenging. To properly assess the anterior peritoneal reflection, it is important that T2 weighted, axial and sagittal images are reviewed²⁷ (Figure 3 and Figure 4).

On axial imaging, the apex of the peritoneum attaches to the anterior rectal wall in a V-shaped configuration. In men this is generally at a point just above the tip of the seminal vesicles; in women the point of attachment is more variable.

On sagittal imaging, the peritoneal reflection may be identified as a low signal linear structure that can be seen extending from the posterior aspect of the dome of the bladder to the ventral aspect of the rectum.

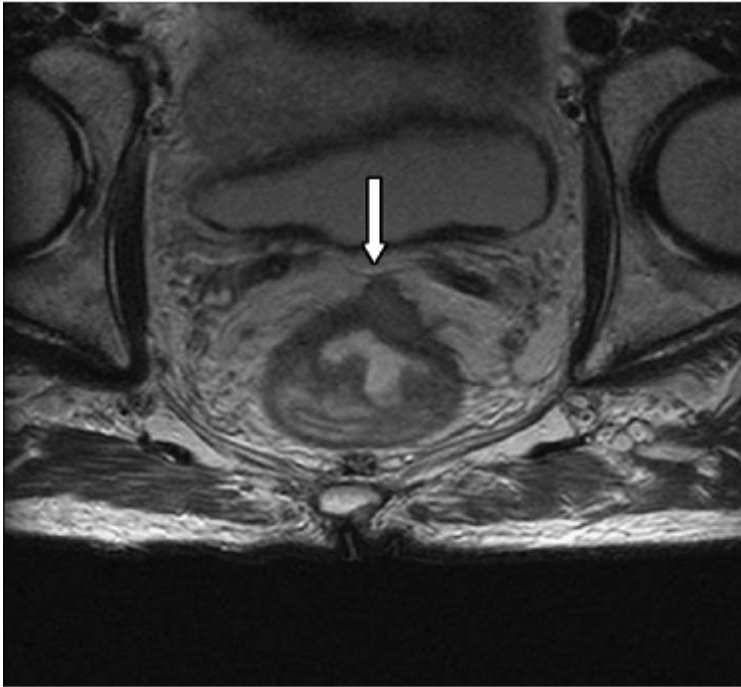
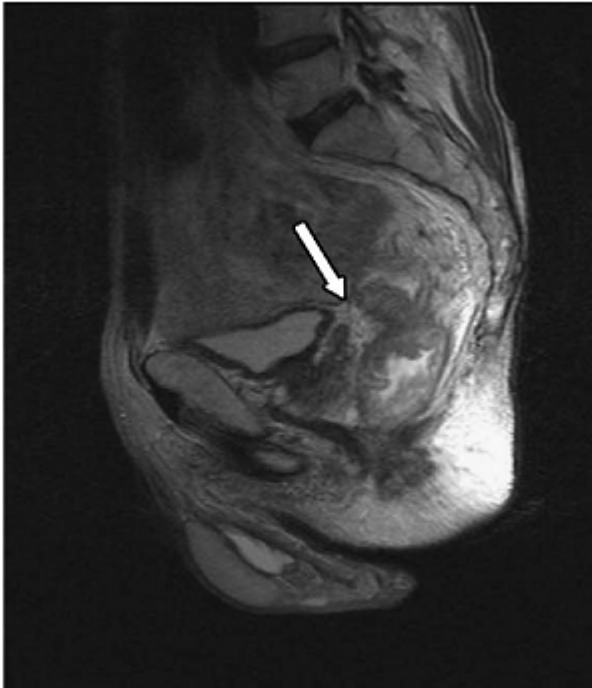


Figure 3:

With permission from Elsevier Salerno G, Daniels IR, Moran BJ, Wotherspoon A, Brown G. Clarifying margins in the multidisciplinary management of rectal cancer: the MERCURYexperience. *Clin Radiol*. Nov 2006;61(11):916-923.



The point at which the peritoneal reflection commences can also be recognized on serial axial MRI through the mesorectum showing the anterior mesorectal fat becoming thinner and thinner. The point where no anterior mesorectal fat is seen is generally where the peritoneal reflection begins.

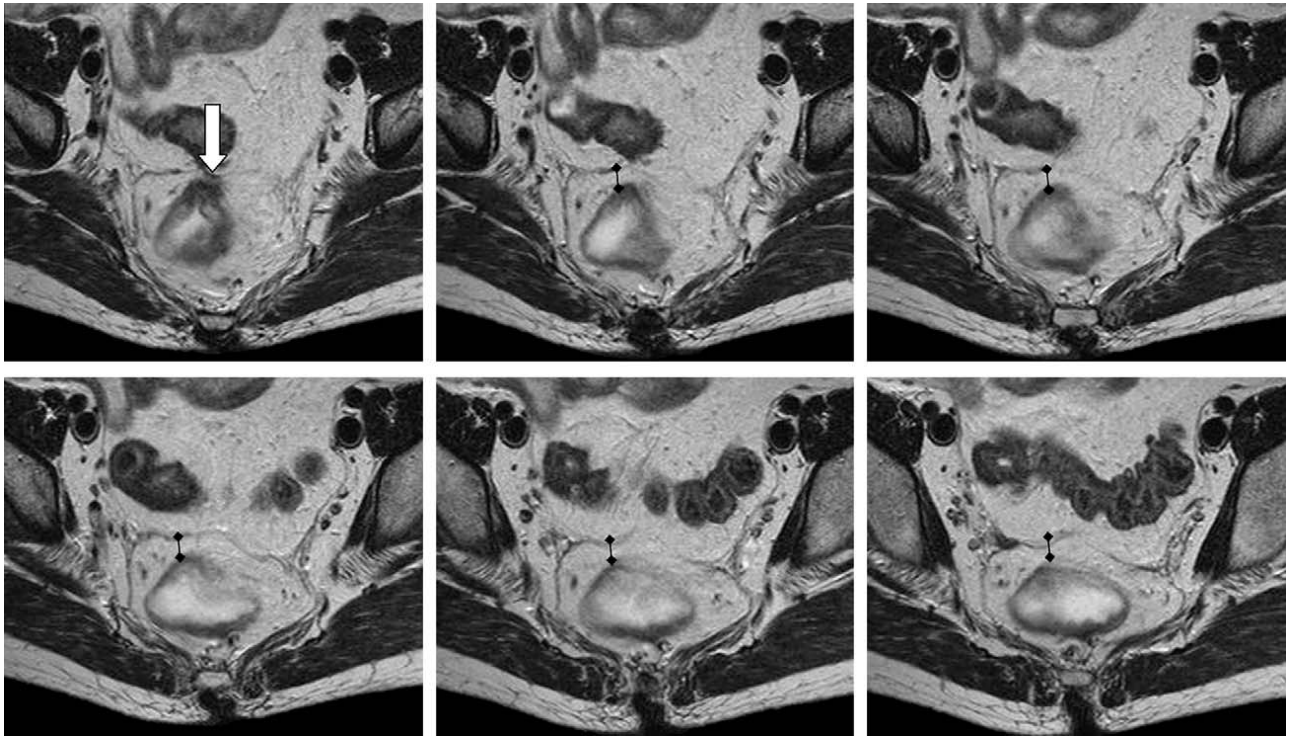


Figure 4:

With permission from Elsevier Salerno G, Daniels IR, Moran BJ, Wotherspoon A, Brown G. Clarifying margins in the multidisciplinary

4. EXTRAMURAL VASCULAR INVASION

Extramural vascular invasion (EMVI) is a pathologic, microscopic feature that refers to invasion of large vessels deep to the muscularis propria and has consistently been shown to be an independent, negative prognostic factor in terms of survival.

An MRI based classification of EMVI proposed by Brown is illustrated below. This classification of EMVI Negative and EMVI Positive will be used for the synoptic MRI report. Using this MRI classification of EMVI, Brown et al. detected EMVI with 62% sensitivity and 88% specificity. In this study, MRI EMVI-positive rectal cancers were found to be associated with advanced pT, pN, and pCRM, synchronous distance metastases and significantly lower recurrence-free survival than MRI EMVI-negative rectal cancers (28).

In a recent MERCURY study, interobserver agreement on detection of EMVI on MRI among 18 experienced radiologists was fair to moderate ($k=0.41$, 95% CI 0.31-0.49).²⁴

In the 2015 template, identification of positive EMVI requires a distance and clockface position in relation to the MRF because surgeons have indicated this is a potential source for threatened margin that they would like to know about preoperatively.

EMVI Negative (Figure 5)

- Pattern of tumour extension through muscularis propria is not nodular or no tumour extension in the vicinity of any vascular structure.
- If stranding is demonstrated near extramural vessels, these vessels are of normal caliber with no definite tumour signal within.

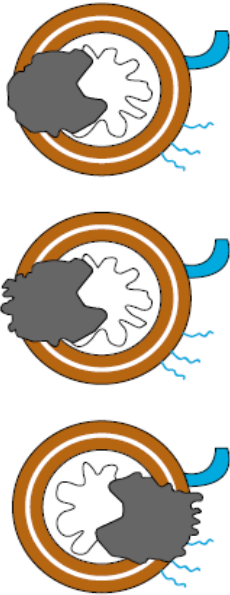

Figure 5:

With permission from Smith NJ, Barbachano Y, Norman AR, Swift RI, Abulafi AM, Brown G. Prognostic significance of magnetic resonance imaging detected extramural vascular invasion in rectal cancer. *Br J Surg*. Feb 2008;95(2):229-236.

EMVI Positive (Figure 6)

- Intermediate signal intensity within vessels in the vicinity of the tumour or obvious irregular vessel contour.

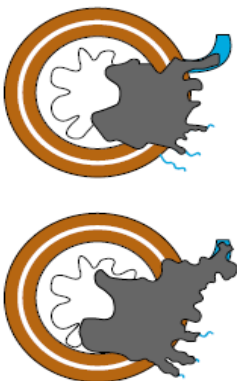


Figure 6:

With permission from Smith NJ, Barbachano Y, Norman AR, Swift RI, Abulafi AM, Brown G. Prognostic significance of magnetic resonance imaging-detected extramural vascular invasion in rectal cancer. *Br J Surg*. Feb 2008;95(2):229-36.

5. MESORECTAL LYMPH NODES AND TUMOUR DEPOSITS

Our literature review showed that MRI has relatively poor accuracy for assessing nodal status (sensitivity 77.0 [95% CI 59-81] and specificity 71 [95% CI 69-84]).

Only three studies have specifically investigated optimal MRI criteria to detect nodal involvement including size, border and signal intensity.^{11,29,30}

The results of these studies suggest that any lymph node or tumour deposit with an irregular border, mixed signal intensity and/or size ≥ 8 mm should be reported as “suspicious”.

- **Any mesorectal lymph node or tumour deposit with an irregular border, mixed signal intensity and/or size ≥ 8 mm in the short axis should be reported as “suspicious”.**

(1) Lymph Node Size

Although a size cut-off of 5 mm is commonly used by clinicians to assess nodal status, there is no evidence in the literature to support this size cut-off (see Table 4). In fact, in one study, 15% of lymph nodes ≤ 5 mm were involved with metastatic disease²⁹ suggesting that there is no size limit below which nodal metastasis can be ruled out. On the other hand, very large lymph nodes (≥ 8 mm) are highly specific for nodal metastasis.^{11,29,30} Therefore, it seems that no matter what size cut-off is used, the overall predictive value of size is poor due to the substantial overlap in size between benign and malignant lymph nodes.

Both Kim and Brown have reported a 100% specificity to detect lymph node metastasis using the following size criteria: 8 mm in the short axis and 1 cm “maximal” diameter, respectively (Table 4). Therefore, for the purpose of the synoptic MRI report, a size criteria of equal to or greater than 8 mm in the short axis has been selected.

Table 4

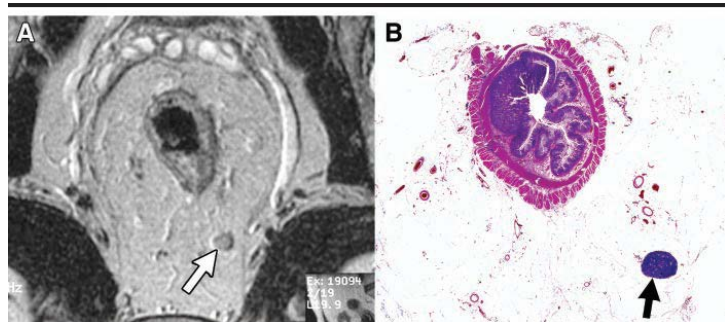
Author		N	Criteria	Sensitivity	Specificity
Matsuoka, 2004		51 patients	6 mm long axis	77.8	78.3
Kim (Beets-Tan), 2004		75 patients	8 mm short axis	45.0	100.0
Brown, 2003	284 lymph nodes	1 cm “maximal diameter”	3.0	100.0	

- **Irregular borders and mixed signal intensity are better predictors of lymph node metastasis than size.**

(2) Border and signal characteristics

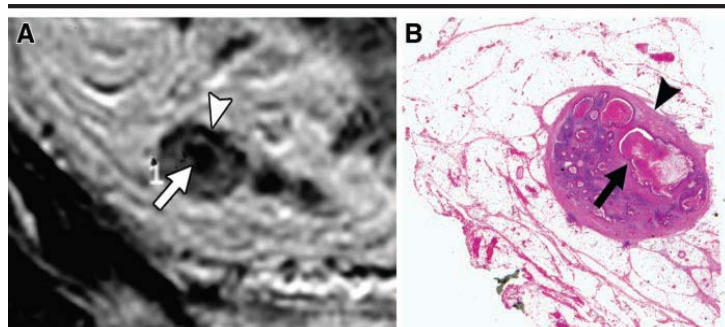
Lymph node border and signal properties appear to be more specific predictors of lymph node metastasis than size criteria. Notably, irregular borders and mixed signal intensity on T2-weighted imaging are individually highly specific

and, in combination, are sensitive and specific to predict lymph node metastasis (sensitivity 85%, specificity 98%)^{11,29,30} (Figure 7).



Smooth Borders and High Signal Intensity

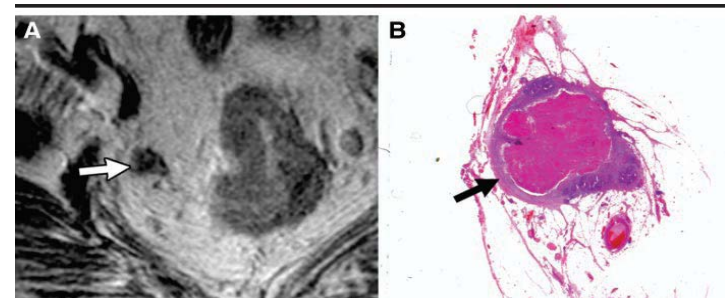
Pathology shows a benign lymph node. Note that there is a low signal band on the left side of the lymph node on the MRI. This is consistent with chemical shift artifact (not mixed signal intensity).



Mixed Signal Intensity

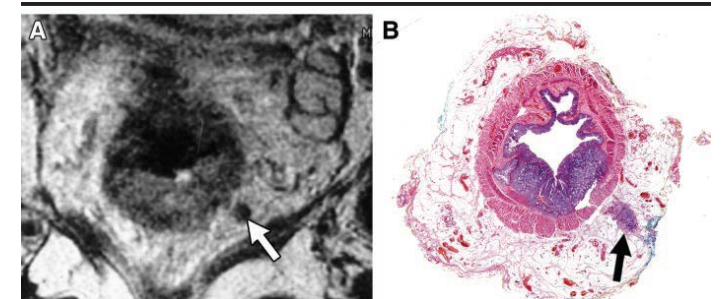
A focus of low signal intensity (arrow) is demonstrated within a predominantly intermediate signal intensity lymph node. Pathology shows tumour with widespread necrosis in the area corresponding to the low signal intensity on MRI (arrow).

The rim of the lymph node is low signal intensity (arrowhead) and represents chemical shift artifact not heterogeneity or mixed signal intensity. This corresponds to normal lymph node capsule on pathology (arrowhead).



Irregular Border and Mixed Signal Intensity

Pathology shows extracellular mucin corresponding to the low signal intensity on MRI.



Irregular Border and Low Signal Intensity

Pathology shows no visible nodal tissue and is consistent with a tumour deposit.

Figure 7:

With permission from Brown G, Richards CJ, Bourne MW, et al. Morphologic predictors of lymph node status in rectal cancer with use of high-spatial-resolution MR

(3) Distribution

- **Most involved mesorectal lymph nodes are most often at the same level or proximal to the level of the tumour.**

Most involved mesorectal lymph nodes are found at or proximal to the level of the tumour.^{31, 32} Although mesorectal lymph nodes below the level of the tumour are uncommon, they may affect the extent of both the radiation field and surgery. For this reason, the location of “suspicious” mesorectal lymph nodes has been included as an item on the synoptic report.

6. EXTRAMESORECTAL LYMPH NODES

- **Any extramesorectal lymph node with an irregular border, mixed signal intensity and/or size ≥ 1 cm in the short axis should be reported as “suspicious”.**

Among published series where pelvic side wall dissection was employed, extramesorectal lymph node metastasis has been reported in up to 17% of patients and is most commonly found in association with locally advanced, low rectal cancers. There is no evidence that treatment of these nodes (with surgery and/or radiation) improves clinical outcomes.³³⁻³⁵ Overall, the optimal imaging criteria for identifying extramesorectal lymph nodes have been less well studied than for mesorectal nodes.^{20,36}

Author	N	Criteria	Sensitivity	Specificity
Arii, 2006	53 patients	7 mm in diameter	56%	97%
Matsuoka, 2007	51 patients	5 mm short axis	67%	83%

Therefore, for the purpose of the synoptic report, we have recommended what is currently being used in clinical practice and consider suspicious extramesorectal lymph nodes to be those with irregular border, mixed signal intensity and/or size ≥ 1 cm in the short axis.

Inferior mesenteric artery nodes were a topic of discussion during the development “Optimization of Preoperative Assessment in Patients Diagnosed with Rectal Cancer”, a multidisciplinary guideline developed since the release of the 2012 synoptic report.³⁷

In that guideline document, the authors state that “MRI is for local staging only and does not adequately assess regional disease at the level of the inferior mesenteric artery; therefore, CT should be used to assess for distant metastases and regional lymph node involvement along the inferior mesenteric artery.”

IMA nodes are important for treatment planning (especially in higher risk patients with positive mesorectal nodes, or positive EMVI) and are inconsistently covered by the imaging field on rectal cancer staging MRI. For this reason they are specifically itemized in the 2015 synoptic report as follows:

ii) Is the IMA node station in the field of view Y or N: No Yes*

*If Yes: are these nodes suspicious No Yes

7. OTHER FINDINGS (COMPLICATIONS, METASTASES, LIMITATIONS OR UNCERTAINTY)

This section is available to record additional items not captured or insufficiently described by the synoptic MRI report.

IMPRESSIONS

This summary statement is intended to highlight the most important elements of the report for the treating physician or multidisciplinary team to understand the prognosis, treatment goals and challenges.

D. REFERENCES

1. Wong RK, Berry S, Spithoff K, et al. Preoperative or postoperative therapy for stage II or III rectal cancer: an updated practice guideline. *Clin Oncol (R Coll Radiol)*. May 2010;22(4):265-271.
2. Kapiteijn E, Marijnen CA, Nagtegaal ID, et al. Preoperative radiotherapy combined with total mesorectal excision for resectable rectal cancer. *N Engl J Med*. Aug 30 2001;345(9):638-646.
3. Sebag-Montefiore D, Stephens RJ, Steele R, et al. Preoperative radiotherapy versus selective postoperative chemoradiotherapy in patients with rectal cancer (MRC CR07 and NCIC-CTG C016): a multicentre, randomised trial. *Lancet*. Mar 7 2009;373(9666):811-820.
4. Sauer R, Becker H, Hohenberger W, et al. Preoperative versus postoperative chemoradiotherapy for rectal cancer. *N Engl J Med*. Oct 21 2004;351(17):1731-1740.
5. Bujko K, Nowacki MP, Nasierowska-Guttmejer A, Michalski W, Bebenek M, Kryj M. Long-term results of a randomized trial comparing preoperative short-course radiotherapy with preoperative conventionally fractionated chemoradiation for rectal cancer. *Br J Surg*. Oct 2006;93(10):1215-1223.
6. Improved survival with preoperative radiotherapy in resectable rectal cancer. Swedish Rectal Cancer Trial. *N Engl J Med*. Apr 3 1997;336(14):980-987.
7. Cancer Care Ontario (2012b). User's Guide for the Synoptic MRI Report for Rectal Cancer Retrieved from <https://www.cancercare.on.ca/common/pages/UserFile.aspx?fileId=133269>
8. Al-Sukhni E, Milot L, Fruitman M, et al. Diagnostic Accuracy of MRI for Assessment of T Category, Lymph Node Metastases, and Circumferential Resection Margin Involvement in Patients with Rectal Cancer: A Systematic Review and Meta-analysis. *Ann Surg Oncol*. Jan 20 2012.
9. Extramural depth of tumor invasion at thin-section MR in patients with rectal cancer: results of the MERCURY study. *Radiology*. Apr 2007;243(1):132-139.
10. Bipat S, Glas AS, Slors FJ, Zwinderman AH, Bossuyt PM, Stoker J. Rectal cancer: local staging and assessment of lymph node involvement with endoluminal US, CT, and MR imaging--a meta-analysis. *Radiology*. Sep 2004;232(3):773-783.
11. Kim JH, Beets GL, Kim MJ, Kessels AG, Beets-Tan RG. High-resolution MR imaging for nodal staging in rectal cancer: are there any criteria in addition to the size? *Eur J Radiol*. Oct 2004;52(1):78-83.
12. Vliegen RF, Beets GL, von Meyenfeldt MF, et al. Rectal cancer: MR imaging in local staging--is gadolinium-based contrast material helpful? *Radiology*. Jan 2005;234(1):179-188.
13. Merkel S, Mansmann U, Siassi M, Papadopoulos T, Hohenberger W, Hermanek P. The prognostic inhomogeneity in pT3 rectal carcinomas. *Int J Colorectal Dis*. Sep 2001;16(5):298-304.
14. Willett CG, Badizadegan K, Ancukiewicz M, Shellito PC. Prognostic factors in stage T3N0 rectal cancer: do all patients require postoperative pelvic irradiation and chemotherapy? *Dis Colon Rectum*. Feb 1999;42(2):167-173.
15. Beets-Tan RG, Beets GL, Vliegen RF, et al. Accuracy of magnetic resonance imaging in prediction of tumour-free resection margin in rectal cancer surgery. *Lancet*. Feb 17 2001;357(9255):497-504.
6. Maier AG, Kersting-Sommerhoff B, Reeders JW, et al. Staging of rectal cancer by double-contrast MR imaging using the rectally administered superparamagnetic iron oxide contrast agent ferristene and IV gadodiamide injection: results of a multicenter phase II trial. *J Magn Reson Imaging*. Nov 2000;12(5):651-660.

17. Matsuoka H, Masaki T, Sugiyama M, et al. Gadolinium enhanced endorectal coil and air enema magnetic resonance imaging as a useful tool in the preoperative examination of patients with rectal carcinoma. *Hepatogastroenterology*. Jan-Feb 2004;51(55):131-135.
18. Videhult P, Smedh K, Lundin P, Kraaz W. Magnetic resonance imaging for preoperative staging of rectal cancer in clinical practice: high accuracy in predicting circumferential margin with clinical benefit. *Colorectal Dis*. Jun 2007;9(5):412-419.
19. Branagan G, Chave H, Fuller C, McGee S, Finnis D. Can magnetic resonance imaging predict circumferential margins and TNM stage in rectal cancer? *Dis Colon Rectum*. Aug 2004;47(8):1317-1322.
20. Arai K, Takifuji K, Yokoyama S, et al. Preoperative evaluation of pelvic lateral lymph node of patients with lower rectal cancer: comparison study of MR imaging and CT in 53 patients. *Langenbecks Arch Surg*. Sep 2006;391(5):449-454.
21. Poon FW, McDonald A, Anderson JH, et al. Accuracy of thin section magnetic resonance using phased-array pelvic coil in predicting the T-staging of rectal cancer. *Eur J Radiol*. Feb 2005;53(2):256-262.
22. Brown G, Richards CJ, Newcombe RG, et al. Rectal carcinoma: thin-section MR imaging for staging in 28 patients. *Radiology*. Apr 1999;211(1):215-222.
23. Battersby NJ, How P, Moran B, et al. Prospective validation of a low rectal cancer magnetic resonance imaging staging system and development of a local recurrence risk stratification model. The MERCURY II Study. *Annals of Surgery*. Mar 2015;0(0): 1-10.
24. Taylor FG, Quirke P, Heald RJ, et al. Preoperative high-resolution magnetic resonance imaging can identify good prognosis stage I, II, and III rectal cancer best managed by surgery alone: a prospective, multicenter, European study. *Ann Surg*. Apr 2011;253(4):711-719.
25. Patel UB, Taylor F, Blomqvist L, et al. Magnetic resonance imaging-detected tumor response for locally advanced rectal cancer predicts survival outcomes: MERCURY experience. *J Clin Oncol*. Oct 1 2011;29(28):3753-3760.
26. Quirke P, Durdey P, Dixon MF, Williams NS. Local recurrence of rectal adenocarcinoma due to inadequate surgical resection. Histopathological study of lateral tumour spread and surgical excision. *Lancet*. Nov 1 1986;2(8514):996-999.
27. Salerno G, Daniels IR, Moran BJ, Wotherspoon A, Brown G. Clarifying margins in the multidisciplinary management of rectal cancer: the MERCURY experience. *Clin Radiol*. Nov 2006;61(11):916-923.
28. Smith NJ, Barbachano Y, Norman AR, Swift RI, Abulafi AM, Brown G. Prognostic significance of magnetic resonance imaging-detected extramural vascular invasion in rectal cancer. *Br J Surg*. Feb 2008;95(2):229-236.
29. Brown G, Richards CJ, Bourne MW, et al. Morphologic predictors of lymph node status in rectal cancer with use of high-spatial-resolution MR imaging with histopathologic comparison. *Radiology*. May 2003;227(2):371-377.
30. Matsuoka H, Nakamura A, Sugiyama M, Hachiya J, Atomi Y, Masaki T. MRI diagnosis of mesorectal lymph node metastasis in patients with rectal carcinoma. what is the optimal criterion? *Anticancer Res*. Nov-Dec 2004;24(6):4097-4101.
31. Engelen SM, Beets-Tan RG, Lahaye MJ, Kessels AG, Beets GL. Location of involved mesorectal and extramesorectal lymph nodes in patients with primary rectal cancer: preoperative assessment with MR imaging. *Eur J Surg Oncol*. Jul 2008;34(7):776-781.
32. Koh DM, Chau I, Tait D, Wotherspoon A, Cunningham D, Brown G. Evaluating mesorectal lymph nodes in rectal cancer before and after neoadjuvant chemoradiation using thin-section T2-weighted

33. Steup WH, Moriya Y, van de Velde CJ. Patterns of lymphatic spread in rectal cancer. A topographical analysis on lymph node metastases. *Eur J Cancer*. May 2002;38(7):911-918.
34. Sugihara K, Kobayashi H, Kato T, et al. Indication and benefit of pelvic sidewall dissection for rectal cancer. *Dis Colon Rectum*. Nov 2006;49(11):1663-1672.
35. Tan KY, Yamamoto S, Fujita S, Akasu T, Moriya Y. Improving prediction of lateral node spread in low rectal cancers--multivariate analysis of clinicopathological factors in 1,046 cases. *Langenbecks Arch Surg*. Jun 2010;395(5):545-549.
36. Matsuoka H, Nakamura A, Masaki T, et al. Optimal diagnostic criteria for lateral pelvic lymph node metastasis in rectal carcinoma. *Anticancer Res*. Sep-Oct 2007;27(5B):3529-3533.
37. Kennedy E, Vella E, MacDonald DB, Wong S, McLeod R, et al. Optimization of preoperative assessment in patients diagnosed with rectal cancer. Toronto (ON): Cancer Care Ontario; 2014 January 15. Program in Evidence-Based Care Evidence-Based Series No.: 17-8.

APPENDIX A: MRI RECTAL STAGING TEMPLATE (2015)



MRI Rectal Staging Template (2015)



This document was developed by Drs Blair Macdonald, Eisar Al-Sukhni, Laurent Milot, Mark Fruitman, Gina Brown, Selina Schmocker and Erin Kennedy for the Cancer Services Innovation Partnership – a joint initiative of Cancer Care Ontario and the Canadian Cancer Society. This template has been updated from 2012.

CLINICAL INFORMATION

i) Clinical requisition: [Free Text]

IMAGING PROCEDURE DESCRIPTION

i) Image quality: Adequate Suboptimal Non-diagnostic
ii) Magnet: 1.5T 3T and Sequences [Free Text] [Insert rectal cancer staging protocol. Should include minimum sequences recommended in User's guide.]

FINDINGS

1. TUMOR LOCATION AND CHARACTERISTICS

- i) Tumor Location (from anal verge): Low 0-5.0cm Mid 5.1-10.0cm High 10.1-15.0cm
ii) Anal verge to distal tumor margin: [_____] cm
iii) Tumor at or below the puborectalis sling: No Yes Uncertain
iv) Distance of lowest extent of tumor from top of anal sphincter: [_____] cm
v) Relationship to the anterior peritoneal reflection: above straddles below not able to assess
vi) Craniocaudal length of the tumor: [_____] cm
vii) Clock face of tumor: [_____] o'clock to [_____] o'clock
viii) Polypoid/Annular/Semi-annular: [_____]
ix) Mucinous: No Yes Uncertain

2. EXTRAMURAL DEPTH OF INVASION AND MR T-CATEGORY

- i) Extramural depth of invasion (Use 0mm for T1 or T2 tumour): [_____] mm
ii) T category:
 T1 or T2
 T2/early T3 (including spiculations)
 T3
 T3/possible T4*
 T4*

* please indicate structures with possible invasion. Specify laterality, sequence and slice#: (see list below)

- | |
|--|
| <ul style="list-style-type: none">• Anterior peritoneal reflection (T4a tumor)• Puborectalis• Levator ani• Obturator• Piriformis• Pelvic bones(specify)• Sacrum (Specify Level)• Bladder• Ureter(s)• Prostate• Uterus• Vagina• Urethra• Vascular Involvement of Iliac Vessels• Other |
|--|

iii) For low rectal tumors (maximum tumor depth at or below the puborectalis sling):

- Not applicable (tumor above the puborectalis sling)
 Level 1 (submucosa only, no involvement of internal sphincter)
 Level 2 (confined to the internal sphincter; no involvement of intersphincteric fat)
 Level 3 (intersphincteric fat involved)
 Level 4 (involves external sphincter or beyond)

3. RELATIONSHIP OF THE TUMOR TO MESORECTAL FASCIA (MRF)

i) Shortest distance ____ mm of the definitive tumour border to the MRF is: At [____] o'clock; OR
 Not able to assess; OR Not applicable (tumor only involves upper anterior peritonealized rectum [T4a])

ii) Are there any tumour spiculations closer to the MRF? No Yes*
*If Yes, spiculations are ____ mm from the MRF at ____ o'clock

4. EXTRAMURAL VENOUS INVASION

i) Extramural Venous Invasion (EMVI) : Absent Equivocal Positive*
*If Positive, EMVI is ____ mm from the MRF at ____ o'clock

5. MESORECTAL LYMPH NODES AND TUMOUR DEPOSITS

i) Any suspicious mesorectal lymph nodes/tumor deposits: No Yes*
(suspicious = mixed signal or irregular borders, and/or short axis ≥ 8 mm NB: Size threshold should not be used alone. Assess signal and borders to increase sensitivity):

* If Yes, the most suspicious node/tumor deposit is [above, at, below] the tumor with minimum distance ____ mm from the MRF at ____ o'clock.

6. EXTRAMESORECTAL LYMPH NODES

i) Any suspicious extramesorectal lymph nodes: No Yes*
(suspicious = mixed signal or irregular borders, and/or short axis ≥ 10 mm. NB: Size threshold should not be used alone. Assess signal and borders to increase sensitivity)

* If Yes, location and laterality of suspicious nodes:

<input type="checkbox"/> Int. Iliac <input type="checkbox"/> R <input type="checkbox"/> L	<input type="checkbox"/> Ext. Iliac <input type="checkbox"/> R <input type="checkbox"/> L	<input type="checkbox"/> Common Iliac <input type="checkbox"/> R <input type="checkbox"/> L	<input type="checkbox"/> Obturator <input type="checkbox"/> R <input type="checkbox"/> L	<input type="checkbox"/> Inguinal <input type="checkbox"/> R <input type="checkbox"/> L	<input type="checkbox"/> Other: _____ <input type="checkbox"/> R <input type="checkbox"/> L
--	--	--	---	--	--

ii) Is the IMA node station in the field of view: No Yes*
*If Yes, are these nodes suspicious No Yes

7. OTHER FINDINGS (COMPLICATIONS, METASTASES, LIMITATIONS)

[Free Text]

IMPRESSIONS

MRI rectal cancer T category is: _____

Maximum EMD of invasion is: _____

Minimum tumor to MRF distance is: _____

Low rectal tumor component: Yes No

Mesorectal nodes/tumor deposits: Negative Suspicious

EMVI: Absent Equivocal Positive

Extramesorectal nodes: Negative Suspicious

Comment: [free text]

APPENDIX B: TNM Staging Classification

Primary Tumour (T)	TX	Primary tumor cannot be assessed.
	T0	No evidence of primary tumor.
	Tis	Tis Carcinoma <i>in situ</i> : intraepithelial or invasion of lamina propria.
	T1	Tumor invades submucosa.
	T2	Tumor invades muscularis propria.
	T3	Tumor invades through the muscularis propria into pericolorectal tissues.
	T4a	Tumor penetrates to the surface of the visceral peritoneum.
	T4b	Tumor directly invades or is adherent to other organs or structures.
Regional Lymph Nodes (N)	NX	Regional lymph nodes cannot be assessed.
	N0	No regional lymph node metastasis.
	N1	Metastases in 1-3 regional lymph node.
	N2	Metastases in ≥ 4 regional lymph nodes.
Distant Metastasis (M)	M0	No distant metastasis.
	M1	Distant metastasis.

Stage Prognostic Groups

Stage	T	N	M
0	Tis	N0	M0
I	T1-T2	N0	M0
II	T3-T4	N0	M0
III	Any T	N1-N2	M0
IV	Any T	Any N	M1

(Source: *Colon and rectum*. In: Edge SB, Byrd DR, Compton CC, et al., eds.: *AJCC Cancer Staging Manual*. 7th ed. New York, NY: Springer, 2010, pp 143-64.)